

Effect of volume on fluorescence intensity and transit time of indocyanine green for sentinel lymph node mapping in a simulated feline tumour model

Hui Yu Lu¹, Charly McKenna², Ann Ram² and Michelle Oblak²

¹ Toronto Animal Health Partners Specialty and Emergency Hospital, North York, ON; ² Department of Clinical Studies, Ontario Veterinary College, University of Guelph, Guelph, ON

Financial support for this work was generously provided by the AHP Veterinary Medical Innovation Research Chair.



Background: Sentinel lymph node (SLN) mapping via a combination of preoperative and intraoperative techniques allows for a better understanding of the primary tumour drainage pathway(s). Intraoperatively, Indocyanine green (ICG) and methylene blue (MB) in combination with near-infrared fluorescence imaging (NIRF) can be used for SLN mapping. Though commonly used in human medicine, these techniques are not yet widely adopted in veterinary medicine.

Methods: Seven healthy 1 year old, male cats were randomly divided into 3 groups with each pelvic limb assigned an injection (either solution A (1mL) or solution B (2mL) of ICG +/- MB). Solutions were injected in 4 quadrants over 30 seconds each, around the simulated tumour on the dorsal metatarsus. The FI was quantified based on the calculation of the corrected total ROI fluorescence (CTRF) using ImageJ software. Cats were monitored for up to 1-month post-procedure for any adverse reactions.

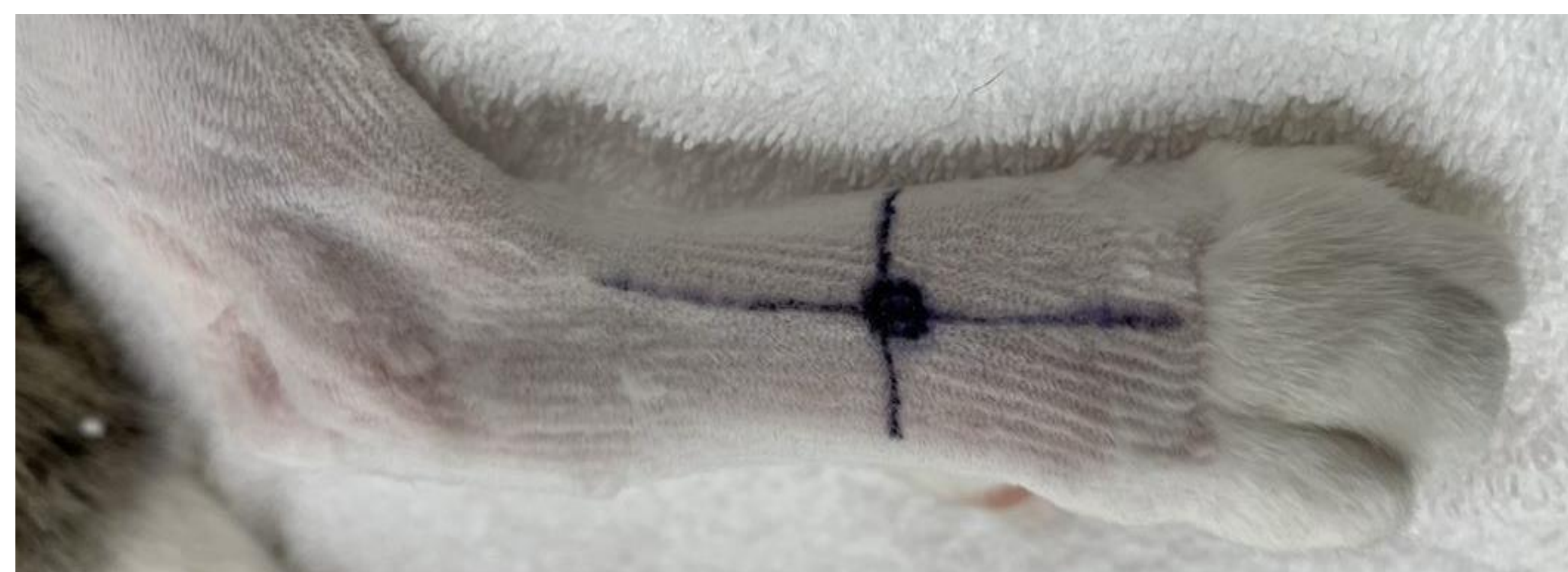

Figure 1: Pelvic limb with simulated tumour and quadrant injection sites drawn with surgical marker.

When a greater volume of dye is injected, the transit time to visualize the SLN is decreased.

($p = 0.001$; range 0.5 – 3.42 minutes)

FI is not affected by the volume of dye (1mL vs 2mL), type of dye (ICG vs ICG-MB), or the timing of massage at the injection site.

Results:

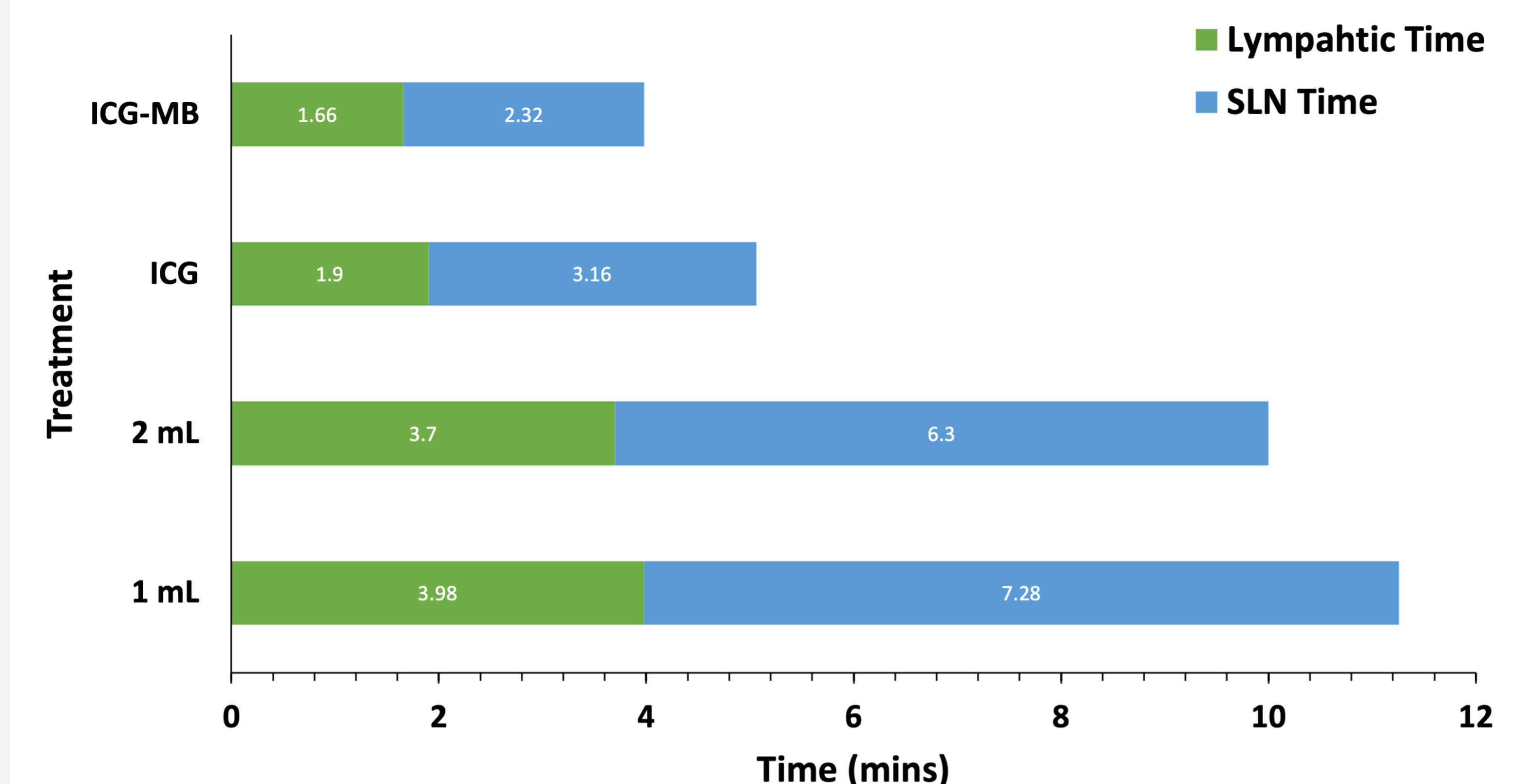


Figure 2: Time (in minutes) to fluorescence detection at the lymphatic tract and sentinel LN between the volumes (1mL vs 2mL) and type of dye injected (ICG vs ICG-MB).

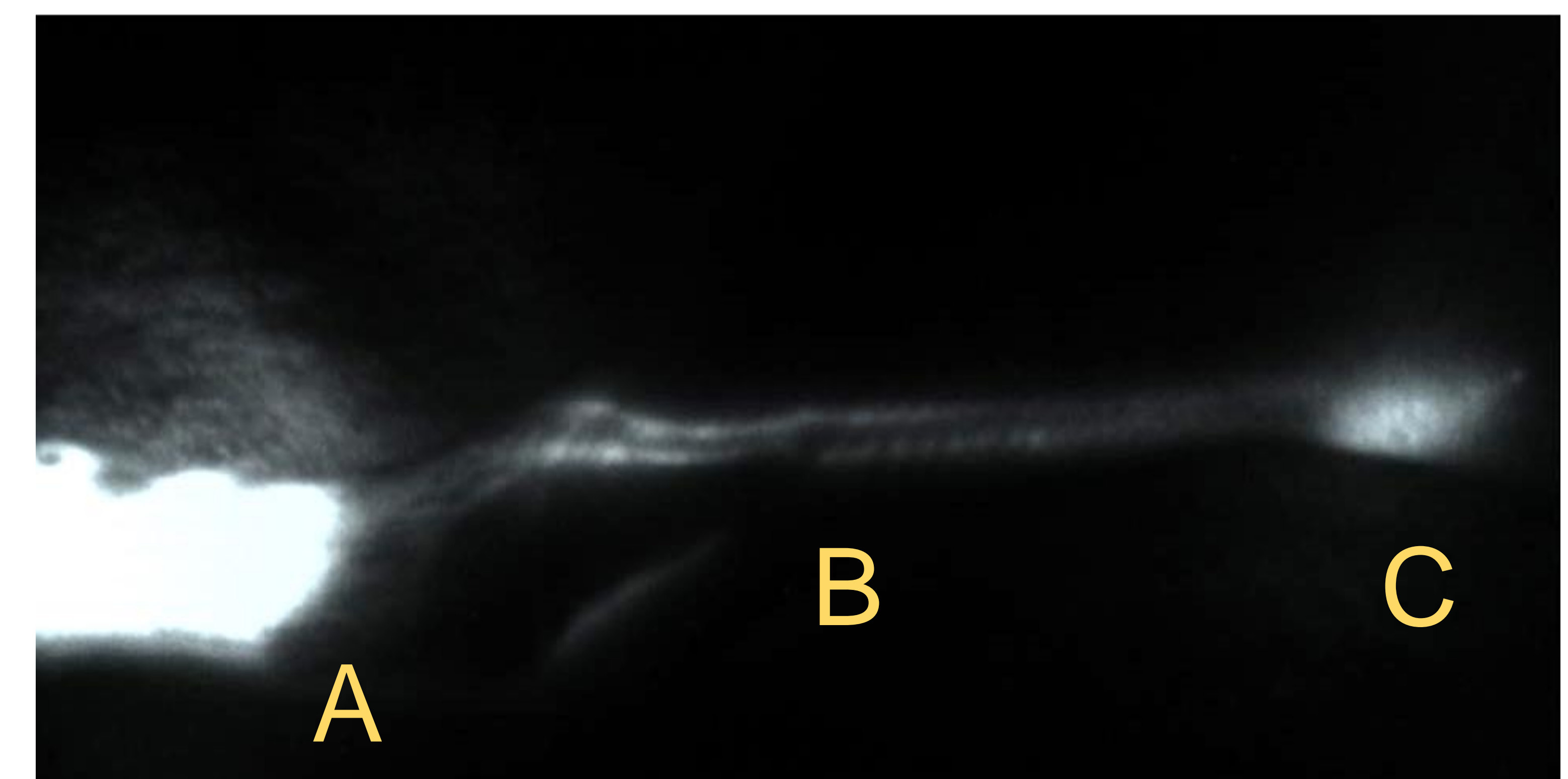


Figure 3: NIRF image of the injection site (A), lymphatic tract (B), and popliteal lymph node (C) at 15 minutes following injection. The pelvic limb of each cat was clipped prior to injections and imaging.

Significance: Percutaneous injections of ICG +/- MB were well-tolerated in healthy cats, therefore intraoperative SLN mapping with ICG +/- MB should be considered in cats with neoplastic disease.